

# T CELL LYMPHOMA ANALYSIS

Charles Goolsby, Ph.D.  
Floyd E. Patterson Research Professor of Pathology  
Northwestern Feinberg School of Medicine  
c-goolsby@northwestern.edu

Charles Goolsby, PhD

# T CELL LYMPHOMA ANALYSIS

- Diverse group of malignancies
- Pathology/clinical driven classification
  - .....
  - Extranodal
    - Extranodal NK/T-cell lymphoma, nasal type
    - Enteropathy-type T-cell lymphoma
    - Hepatosplenic T-cell lymphoma
    - Subcutaneous panniculitis-like T-cell lymphoma
  - Cutaneous
    - Blastic NK-cell lymphoma
    - Mycosis fungoides/Sezary syndrome
    - Primary cutaneous anaplastic large cell lymphoma
  - Nodal
    - Peripheral T-cell lymphoma, unspecified
    - Angioimmunoblastic T-cell lymphoma
    - Anaplastic large cell lymphoma
  - .....
- Aberrant immunophenotypes
  - Significant overlap with patterns that can be seen in reactive
  - Clonality
    - $V_{\beta}/V_{\alpha}$  region family specific antibodies
    - Sensitive, Seldom routinely done

Charles Goolsby, PhD

T cell lymphomas and leukemias represent a relatively rare group of malignancies compared to mature B cell lymphomas/leukemias. The immunophenotypic discussion of this group of hematopoietic malignancies is somewhat difficult for several reasons. For all hematopoietic malignancies, the clinical picture is an important aspect for accurate diagnosis. However, for T cell malignancies, it is absolutely critical and in some instances the primary piece driving sub-classification. Thus, the entities can be difficult to discuss from a strictly pathology or immunophenotyping point of view. Also, in many instances, although a specific sub-classification may have a predominant immunophenotypic pattern, there is often variability with markedly different immunophenotypic subsets even within a given entity. To some extent the later is changing in evolving classification systems but nonetheless remains. In addition, at least compared to B cell processes, there is significantly more overlap of immunophenotypic patterns seen in some T cell malignancies with patterns that can be seen in marked reactive T cell processes or populations. Lastly, although sensitive and specific clonality detection can be done by flow cytometry in T cells, in practice, it is seldom routinely done due to expense and complexity compared to kappa/lambda analysis in B cells.

# T CELL LYMPHOMA ANALYSIS

- Examples
  - **Mycosis Fungoides/Sezary Syndrome**
  - **Adult T Cell Leukemia/Lymphoma (ATLL)**
  - **T Lymphoblastic Lymphoma/Leukemia**
  - Lymphomas with NK or cytotoxic features
  - **Gamma/delta T Cell Lymphoma**
  - **Angioimmunoblastic T Cell Lymphoma (AILT)**
  - Peripheral T cell lymphoma, unspecified
  - Enteropathy-type T cell lymphoma
  - Anaplastic large cell lymphoma (ALCL)
  - .....
  - **Clonality**

Charles Goolsby, PhD

The goal of this presentation is to illustrate some common themes in flow cytometry immunophenotypic analysis of T cell malignancies. Although there are a large number of T cell malignancies, a partial list of which is above, we will try to illustrate these points with examples from five subtypes (highlighted above). In addition, a brief discussion with examples of clonality detection, or surrogates of clonality, will be done at the end of the presentation.

## Mycosis Fungoides/Sezary Syndrome: Pan T cell antigen loss/alteration

- Mycosis Fungoides (MF)
  - Most common Cutaneous T-cell lymphoma (CTCL) (~50% of primary cutaneous lymphomas)
  - Epidermotropic clonal T cell malignancy
  - Skin lesions (patches, plaques, etc)
    - Cells with characteristic “cerebriform” nuclei
  - Primarily older adults
    - Slight male predominance (1.5 to 2:1)
  - Indolent
    - 85-90% 5 year survival
- Sezary syndrome
  - Many common pathology/immunophenotypic features with MF
  - Disease of adults
  - Skin lesions and generalized lymphadenopathy
    - Malignant cells in skin, lymph node, and peripheral blood
      - Refer to Blood 105:3768, 2005 for diagnostic criteria
  - Aggressive disease
    - ~25% 5 year survival

Charles Goolsby, PhD

Although not all, many, if not most, T cell malignancies exhibit loss or alteration in expression of one or more pan T cell associated antigens. The archetypical example of this is mycosis fungoides and Sezary syndrome. A brief description of these diseases is listed above. Although quite different in prognosis, these diseases share many common pathology features and cellular morphology.

## T CELL LYMPHOMA ANALYSIS: Mycosis Fungoides/Szeary Syndrome

- Immunophenotype
  - Mature T cell malignancy (surface CD3<sup>+</sup>)
    - Altered CD3 expression can be seen
  - Most frequently, T helper immunophenotype
    - CD3<sup>+</sup>CD4<sup>+</sup>
  - Characteristically, CD7<sup>-</sup>
    - May be partial
      - Some can be CD7<sup>+</sup>
    - Typically, CD2<sup>+</sup>, CD5<sup>+</sup>
      - But deletion can be seen
  - Altered expression of any of the pan T cell antigens can be seen
  - Most frequently, CD25<sup>-</sup>
    - CD25<sup>+</sup> in ~10-20% of cases

Charles Goolsby, PhD

In addition, they share the same immunophenotypic characteristics described above.

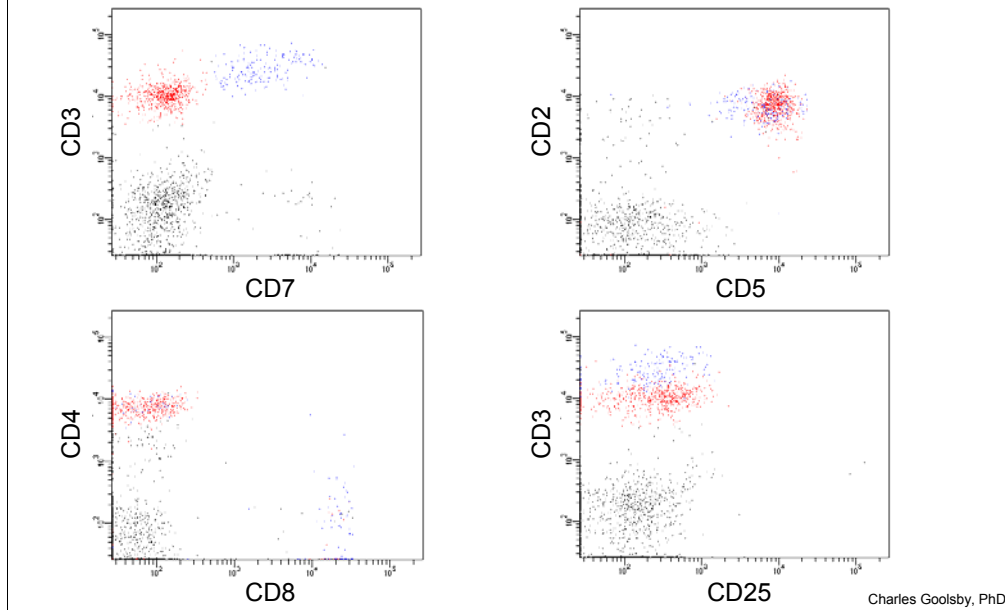
## T CELL LYMPHOMA ANALYSIS: Mycosis Fungoides/Szeary Syndrome

- 74 year old male
- Complaints of erythroderma and plaques on his trunk for 6-9 months
- WBC: 12.7
  - 62% Lymphocytes
  - 6% Monocytes
  - 32% Granulocytes
- Examination of the peripheral smear showed abnormal lymphocytes
- Peripheral blood sample received

Charles Goolsby, PhD

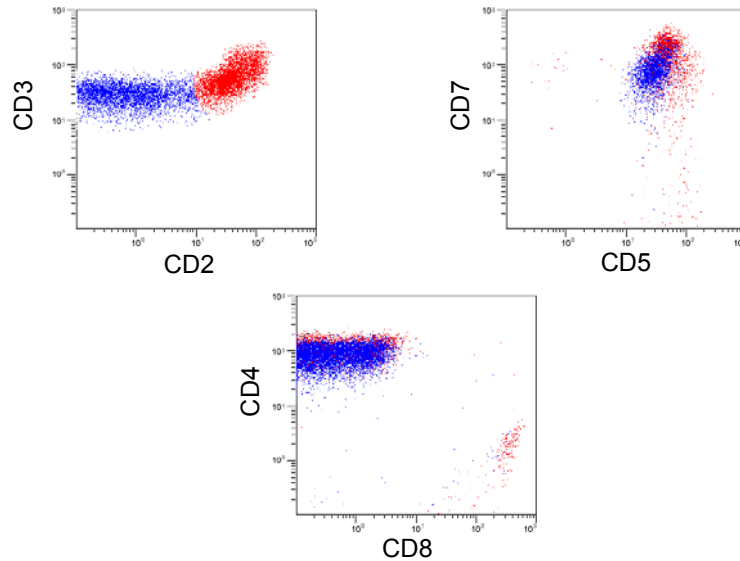
The next two slides present a “classic” case of an older gentleman with Szeary syndrome who presented with persistent erythroderma and skin plaques and an absolute lymphocytosis with circulating “Szeary” cells.

## T CELL LYMPHOMA ANALYSIS: Mycosis Fungoides/Szeary Syndrome



A "classic" Szeary syndrome immunphenotype is shown above. The above histograms are all gated on lymphocytes based on forward and side scattered light intensity as well as CD45 characteristics. The normal and abnormal T cells are shown in blue and red, respectively. The abnormal T cells are CD7<sup>-</sup> and have slightly dimmer surface CD3 staining than the normal T cells. The abnormal cells are also CD2<sup>+</sup>, CD5<sup>+</sup>, CD4<sup>+</sup>, CD8<sup>-</sup> and CD25<sup>-</sup>.

## T CELL LYMPHOMA ANALYSIS: Mycosis Fungoides/Szeary Syndrome

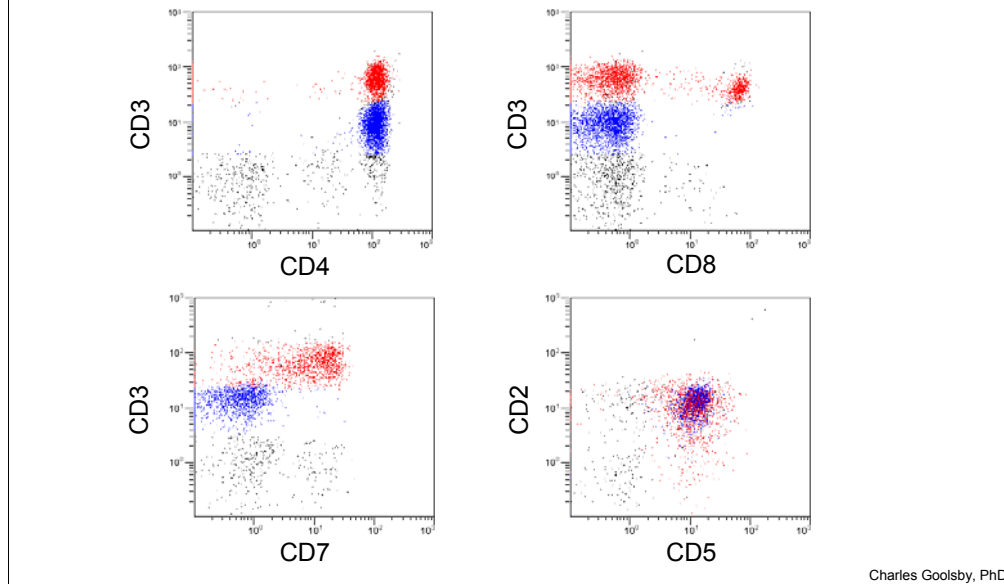


Charles Goolsby, PhD

In this slide are the immunophenotypic results from a different patient showing less typical immunophenotype for Szeary/mycosis fungoides. In this case the abnormal T cells are shown in blue and they also have dimmer than normal surface CD3 staining intensity, are CD5+ but in contrast to the previous are CD7+ but exhibit dim CD2 to CD2- staining. The abnormal cells were CD4+ and CD8-



## T CELL LYMPHOMA ANALYSIS: Mycosis Fungoides/Szeary Syndrome



Here is one additional example showing a discretely dimmer surface CD3 intensity, CD7<sup>-</sup> abnormal T cell population (blue) which is CD4<sup>+</sup>, CD8<sup>-</sup>, CD2<sup>+</sup>, and CD5<sup>+</sup>. This case nicely demonstrates the altered pan T cell antigen intensity (in this example CD3) even when overt loss of that antigen is not seen.

## T CELL LYMPHOMA ANALYSIS: Adult T Cell Leukemia/Lymphoma (ATLL)

Mature clonal T cell process

- Most often presents with lymph node and peripheral blood involvement
- Skin lesions
  - Histopathologically can be difficult to distinguish from MF
- Frequent hepatosplenomegaly
- Prognosis
  - Acute ATLL, lymphomatous variant: poor <1 year
  - Chronic and smoldering variants: better prognosis
- HTLV-1 linked

Charles Goolsby, PhD

Adult T cell leukemia/lymphoma is a mature (surface CD3+) T cell malignancy which shares similar immunophenotypic and histopathologic features with mycosis fungoides/Szeary syndrome. The disease is endemic to Japan, Caribbean and parts of central Africa. Hepatosplenomegaly is frequent particularly in the acute form. With the acute form disseminated disease can be seen, however, the lymphomatous variant frequently presents with lymphadenopathy but usually does not involve the peripheral blood. In the chronic and smoldering variants, there are often skin lesions with an elevated WBC, although there may be few atypical cells

## T CELL LYMPHOMA ANALYSIS: Adult T Cell Leukemia/Lymphoma (ATLL)

- Immunophenotype
  - Mature (surface CD3+) T cell malignancy
  - Most frequently, T helper cell immunophenotype
    - CD3+CD4+
    - Rarely, CD8+ or CD4+/CD8+
  - Typically, sCD3+, CD5+, CD2+
  - Characteristically, CD7- or dim CD7
    - Alterations in expression of other pan T cell antigens can be seen
  - Characteristically, and consistently, CD25+

Charles Goolsby, PhD

Above is summarized the typical, or most frequent, immunophenotype of this disease which is very similar to mycosis fungoides(MF)/Szeary syndrome (surface CD3+(sCD3), CD2+, CD5+, CD7-, CD4+, CD8-), although as noted some variability can be seen as is also true in MF/Szeary. In contrast to MF/Szeary, virtually all ATLL cases will be CD25+, possibly related to the viral etiology (HTLV-1) of this disease. Although MF/Szeary can be CD25+, it is in a minority of cases. Thus, a CD25+ result coupled with the other immunophenotypic results discussed here raises ATLL in the differential and HTLV-1 serologies may be helpful in that context.

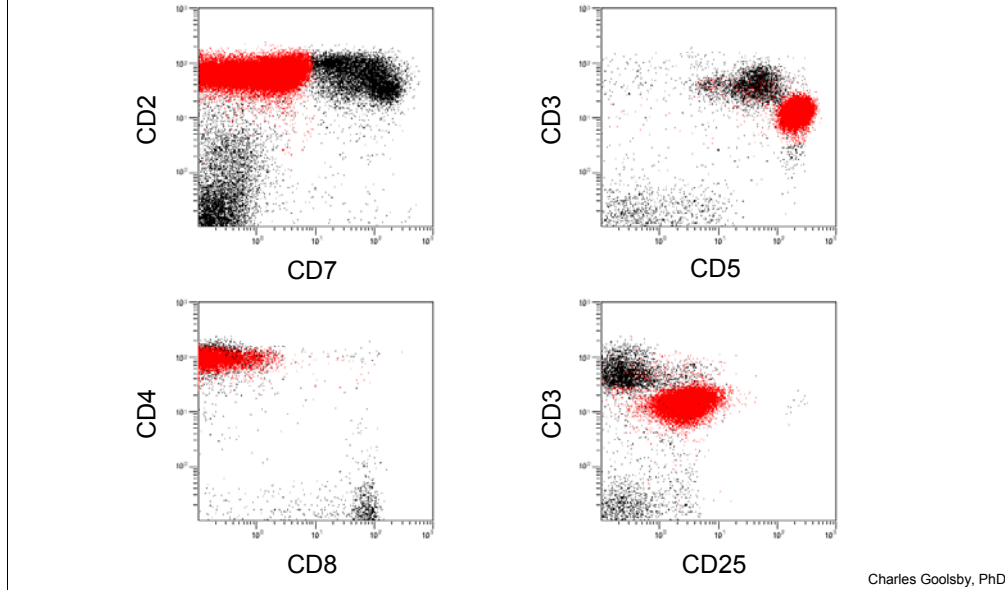
## T CELL LYMPHOMA ANALYSIS: Adult T Cell Leukemia/Lymphoma (ATLL)

- 67 year old male
- Jamaican resident
- Cervical lymphadenopathy
- WBC: 75.0
  - 70% Lymphocytes
  - 3% Monocytes
  - 27% Granulocytes
- Peripheral blood sample received

Charles Goolsby, PhD

Shown in the next slide are a typical example of flow cytometry results in ATLL. The presenting characteristics of the patient are given above.

## T CELL LYMPHOMA ANALYSIS: Adult T Cell Leukemia/Lymphoma (ATLL)



Above is shown the flow cytometry results for this patient who was diagnosed with ATLL. Note the abnormal cells shown in red which are dim CD7 to CD7-, distinctly dimmer sCD3, distinctly brighter CD5, CD2+, CD4+, CD8-, and CD25+.

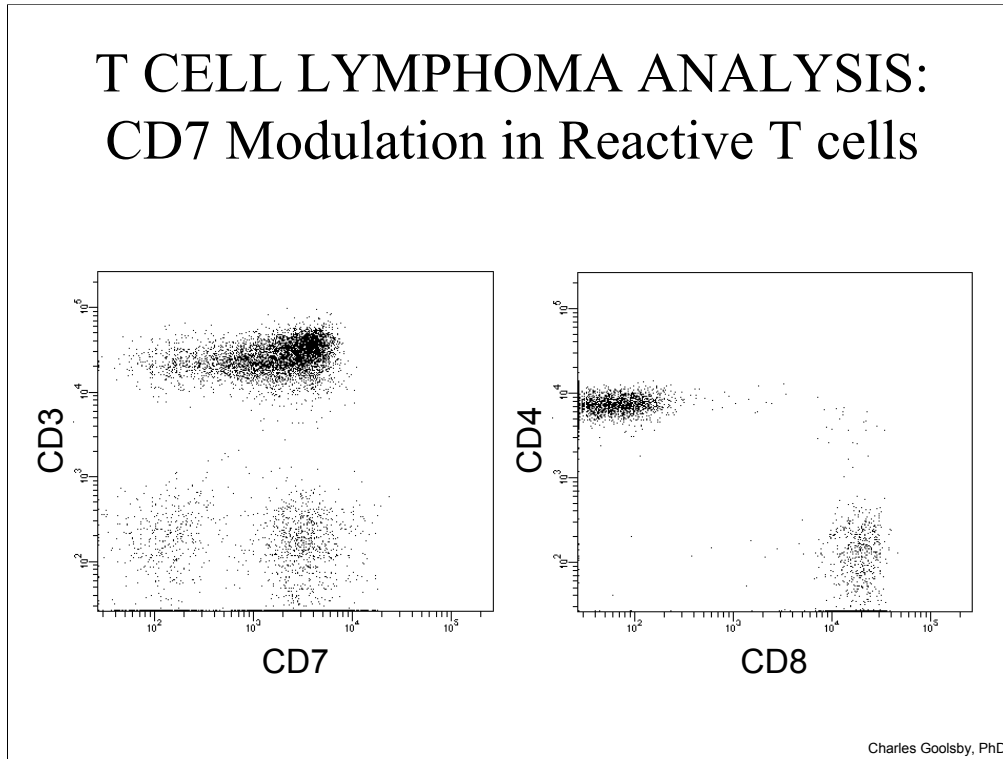
## T CELL LYMPHOMA ANALYSIS: CD7 Modulation in Reactive T cells

- Reactive T cells can modulate pan T cell antigen expression
  - Most temporally short
  - CD7 can be significant and persistent
- Dim CD7 to CD7- reactive T cells can be CD4+
  - CD25+, CD26+ (activated immunophenotype)
- Overlaps with MF/Szeary and ATLL immunophenotype
  - Pattern of CD7 staining can be helpful

Charles Goolsby, PhD

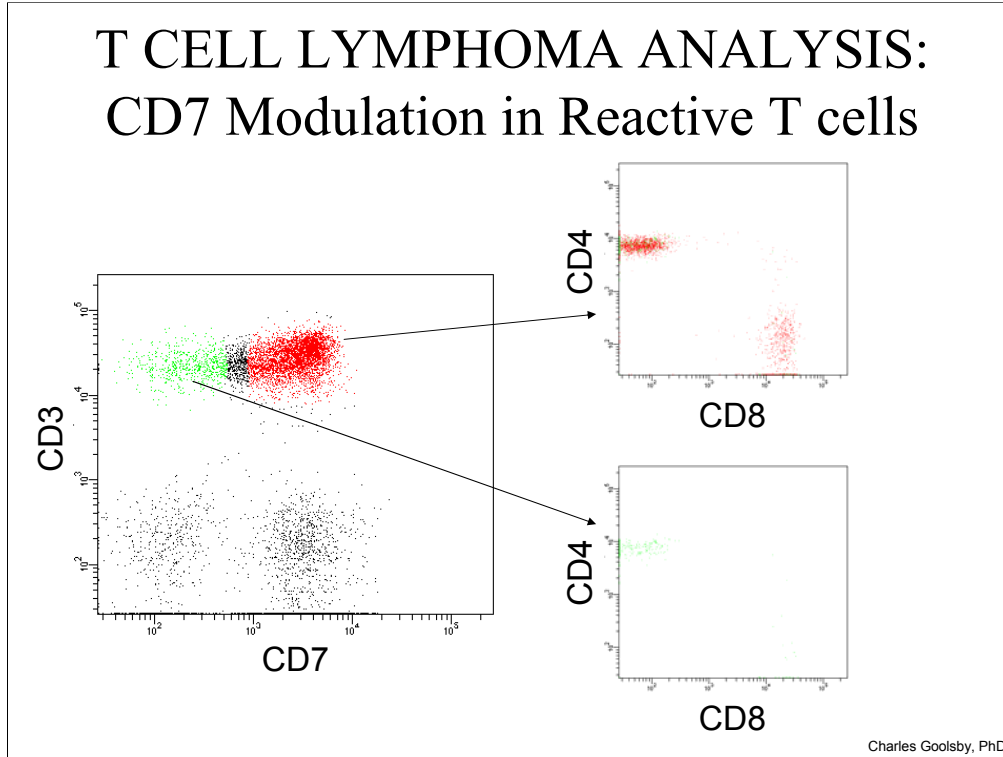
Important in assessing when minimal disease levels may be present in a sample such as post-therapy is recognition of the significant similarity in immunophenotypic features seen in MF/Szeary and in some reactive T cell subsets. As mentioned earlier, the overlap in immunophenotypic patterns seen in some T cell lymphomas/leukemias with reactive T cell subsets is a recurring theme in analysis of T cell processes. In the case of MF/Szeary, the CD7- (or dim), CD4+ characteristic immunophenotype is also frequently seen in reactive, or activated, T cell subsets. In fact, important to note, is that modulation in expression level of the pan T cell antigens in general, not just with CD7, can be seen in reactive T cells.

## T CELL LYMPHOMA ANALYSIS: CD7 Modulation in Reactive T cells



The pattern of CD7 staining can be helpful. The pattern of CD7 staining seen above in which the vast majority of the T cells (surface CD3+) are bright CD7+ but one sees a small, heterogeneous tail of dimmer CD7 staining is typical of that seen in reactive T cells and can be frequently seen. Contrast this pattern of CD7 staining to the discretely CD7- staining in the archetypical MF/Szeary case shown six and eight slides before. However, this is not always clear, and as also shown above, the CD7 staining is sometimes more heterogeneous in MF/Szeary. In addition, in some reactive cases, the down-regulation of CD7 can be quite pronounced. If selecting the dimmer CD7 to CD7- cells shows a mixture of CD4+ and CD8+ cells, this can be somewhat re-assuring that the cells are likely reactive, however, .....

## T CELL LYMPHOMA ANALYSIS: CD7 Modulation in Reactive T cells



However, in some reactive cases, dim CD7 to CD7<sup>-</sup> reactive T cells can be very significantly skewed to the CD4<sup>+</sup> subset, sometimes virtually all CD4<sup>+</sup>, as shown in the example above. Thus, although seeing a nice mixture of CD4 and CD8 cells can be somewhat re-assuring, seeing all CD4<sup>+</sup> does not necessarily mean that residual disease is likely present. This has led to desire for other markers that might be useful in distinguishing malignant/abnormal cells in MF/Szeary from potentially similar dim CD7/CD7<sup>-</sup> reactive T cells.



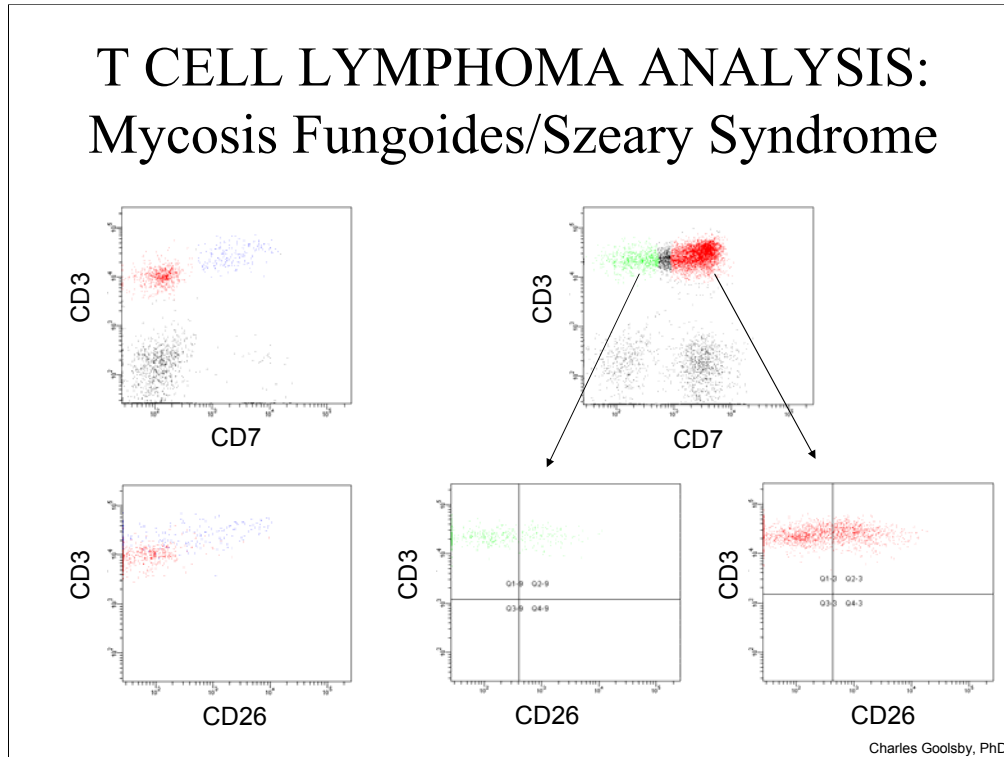
## T CELL LYMPHOMA ANALYSIS: Mycosis Fungoides/Szeary Syndrome

- CD26 T cell activation antigen
  - Membrane and secreted protein
  - Modulates chemokine activity
  - Co-stimulatory molecule (both CD3 and CD2 pathways)
- Reported to be useful differentiating Szeary cells from reactive T cells
  - Jones et al, Am J Clin Path 115: 885, 2001
  - Bernengo et al, Br J Dermatol 144(#1):125, 2001
  - Circulating Szeary cells frequently CD26-
    - Reactive Dim CD7 to CD7- cells which would be CD26+

Charles Goolsby, PhD

CD26 is a dipeptidyl aminopeptidase that is up-regulated in activated T cells. Although other T cell activation antigens have also been used, CD26 has proved to be useful in a subset of MF/Szeary patients to differentiate reactive (CD26+) from residual malignant cells which are frequently CD26-.

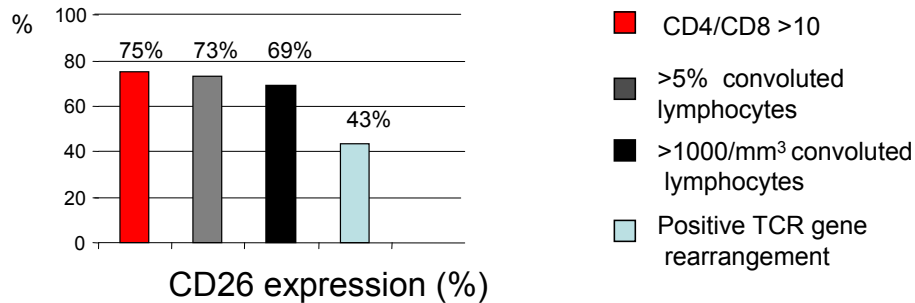
## T CELL LYMPHOMA ANALYSIS: Mycosis Fungoides/Szeary Syndrome



In this slide, the two histograms on the left show results for an archetypical MF/Szeary case. The top distribution on the left showing surface CD3 versus CD7 with the normal cells (CD3+CD7+) in blue and the abnormal (CD3+CD7-) shown in red. The bottom histogram (CD3 versus CD26 intensity) shows the heterogeneous dim to moderate positive CD26 staining in the normal cells and the CD26- staining in the abnormal cells. On the right are shown results for a sample with reactive T cells. The bottom two histograms on the right show similar dim to moderate heterogeneous CD26 staining in both the CD3+, bright CD7+ cells and in the CD3+, dim CD7+ to CD7- cells in this sample which earlier was shown to be all CD4+. Please note the cursors in these distributions are added only as references and do not indicate positive and negative cells.

## T CELL LYMPHOMA ANALYSIS: Mycosis Fungoides/Szeary Syndrome

- How useful?



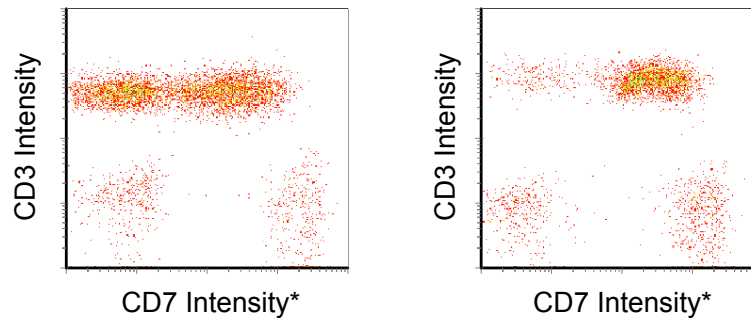
- Overall, ~64% of cases show CD4+CD26-
  - Keleman et al, AJCP 129:149-156, 2008

Charles Goolsby, PhD

Data published from our group on a series of MF/Szeary patients showed that CD26- staining is seen in approximately 2/3 of cases. Thus, in the differential of potential residual MF/Szeary versus reactive T cells finding a dim CD7 to CD7-, CD4+ population which is CD26- is helpful in that it does not represent a reactive T cell population and most likely represents residual disease. However, if these cells are CD26+, the result is less helpful in that they could represent either a reactive T cell subset or potential residual disease.

# T CELL LYMPHOMA ANALYSIS

## Epitope deletion/masking



\* Independent anti-CD7 antibodies

Charles Goolsby, PhD

A cautionary note, or warning, when assessing loss of an antigen that lack of staining with a single monoclonal antibody does not always mean lack of antigen. Monoclonal antibodies recognize a very small portion of an antigen, typically a small number of amino acids (AA) in a 3-dimensional conformation. Thus, mutations within the genes coding for those AA can remove, or change, an AA, or alternatively, a mutation in another part of the antigen may change the folding of that protein altering the 3-dimensional structure. It is possible even for mutations in other molecules to change how the antigen of interest is presented, and thus, is accessible for antibody binding. Any of these alterations may remove binding of a single monoclonal antibody and has been termed epitope deletion/masking. Thus, lack of staining with a single monoclonal antibody does not necessarily mean lack of antigen. Use of an independent monoclonal antibody directed against that antigen can help to ensure that the antigen is actually missing versus just altered removing staining for the test antibody. By an independent antibody, we are referring to one directed against a different portion of the antigen. The chances that a mutation would remove, or alter, two independent small sites on the antigen is much lower than just one. This is well appreciated by the flow cytometry community for some antigens such as kappa and lambda with the need for assessment of more than one set of independent anti-kappa/anti-lambda antibodies being necessary to verify lack of staining when no staining has been seen with one set of antibodies. However, this can potentially happen with any antigen. For example, we have seen this with CD5 and with CD23 in CLL, HLADR in AML, and with pan T cell antigens in T cells.

Above is an example for CD7. With the first anti-CD7 antibody used (shown on left), there appears to be a distinct CD7- population within the surface CD3+ T cells. However, when an independent anti-CD7 antibody is used (shown on the right), we see that in fact those cells have the CD7 antigen. With this independent antibody, those cells are now CD7+ and we see only the dim heterogeneous small tail of CD7 staining typical of reactive T cells. Thus, the take home message is that for any antigens critical for the differential diagnosis to ensure that lack of staining for antigen actually represents lack of that antigen, one should test with at least two independent monoclonal antibodies. In practice, technically, other issues such as affinity/avidity or sensitivity with different fluorochromes may also impact testing with an independent antibody that could yield staining when another antibody did not and are not truly epitope deletion/masking, however, clinically determining which of the reasons is true is not as important as the question is presence or absence of the antigen.

## T CELL LYMPHOMA ANALYSIS: Lymphoblastic Lymphoma/Leukemia

- Proliferation of malignant “blast” cells
  - T-LBL and T-ALL same disease
  - T-LBL ~80-85% of lymphoblastic lymphomas
  - Primarily, young males
- Most frequently presents with mediastinal mass
  - Can involve lymph node, spleen, skin, liver
  - Pleural effusions common
  - Peripheral blood/bone marrow (if extensive T-ALL)

Charles Goolsby, PhD

In the context of T cell lymphoblastic lymphoma/leukemia (T-LBL/T-ALL), the next set of slides is to further illustrate in a different way the utility of antigen expression patterns in the work-up of T cell processes.

## T CELL LYMPHOMA ANALYSIS: Lymphoblastic Lymphoma/Leukemia

- Immunophenotype
  - Most frequent is “common” thymocyte immunophenotype
    - sCD3-, cCD3+, CD2+, CD5+, CD7+
      - Less often dim sCD3 or sCD3+ staining can be seen
    - CD4+/CD8+, CD1a+
    - TdT+, CD34-
    - Frequently, CD10+
    - Loss or modulation of CD2, CD5, or CD7 can be seen
    - Aberrant expression of CD13 and/or CD33 can be seen
      - CD79a rarely
  - Although rarer, more “immature” immunophenotypes can be seen such as CD34+

Charles Goolsby, PhD

The most frequent immunophenotypes of T-LBL/T-ALL are described above. It should be noted that there is also a rare gamma/delta variant of this malignancy which is typically surface CD3+, CD2+, CD5+, CD7+, CD4-, CD8-, gamma/delta+, and TdT+ as well as having a “blast” morphology. As with most T cell malignancies, alterations in one or more of the pan T cell antigens can occur.

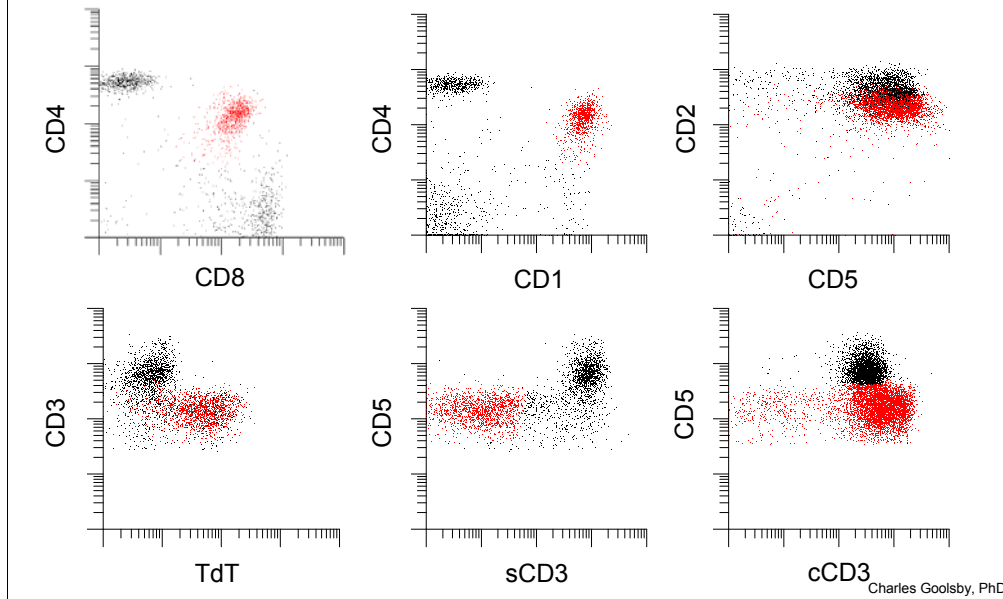
## T CELL LYMPHOMA ANALYSIS: Lymphoblastic Lymphoma/Leukemia

- 14 year old male
- Shortness of breath and cough
- Chest discomfort
- Chest x-ray revealed a large mediastinal mass and left pleural effusion
- CBC: normal
- Received mediastinal mass biopsy

Charles Goolsby, PhD

## T CELL LYMPHOMA ANALYSIS: Lymphoblastic Lymphoma/Leukemia

2



Shown above is an example of immunophenotypic results for T lymphoblastic lymphoma/leukemia. The abnormal cells are shown in red with a typical pattern of antigen expression (CD4/CD8 co-expression, CD1a+, predominantly surface CD3- and cytoplasmic CD3+, CD2+, CD5+, and TdT+). In some cases, alteration of the pan T cell associated antigens, CD2, CD5, and/or CD7 can be seen, even in this example the CD2 staining is dimmer than that in the normal T cells seen (most likely from contaminating blood in the specimen)



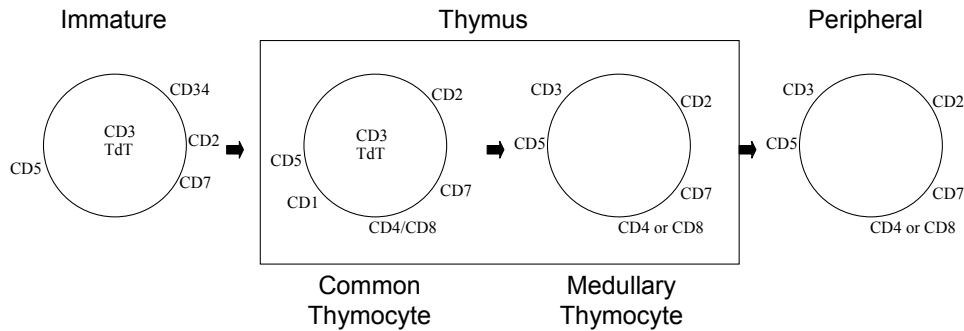
## T CELL LYMPHOMA ANALYSIS: Lymphoblastic Lymphoma/Leukemia

- Frequent differential in patient with mediastinal mass
  - Thymoma vs T-LBL/T-ALL
  - Immunophenotype of T-LBL/T-ALL can overlap with normal immature thymic T cells
    - T cells differentiate in the thymus
    - Normal thymus mixture of T and non-hematopoietic cells
      - Immature, “common thymocyte” T cells
      - More mature, medullary thymocytes
      - Mature T cells exiting to the periphery

Charles Goolsby, PhD

A frequent differential is a patient presenting with a mediastinal mass is thymoma (an epithelial tumor in which one can also see normal maturing thymic T cells) versus T-LBL/T-ALL. The immunophenotype of T-LBL/T-ALL overlaps with a significant subset of normal maturing thymic T cells. Here the pattern of staining for the antigens shown in the above example of T-LBL/T-ALL can be helpful in differentiating the two.

# T CELL LYMPHOMA ANALYSIS: Lymphoblastic Lymphoma/Leukemia



- Normal is a process of differentiation
  - Common and medullary populations
    - Transition immunphenotypes as well
- In some cases, pattern of these markers can be helpful

Charles Goolsby, PhD

Above is shown a schematic representation of T cell maturation showing the maturation of T cells in thymus from that of a common thymocyte T cell (cytoplasmic CD3+, surface CD3-, CD2+, CD5+, CD7+, co-expression of CD4/CD8, CD1a+, and TdT+) to that of mature T cell in the medullary regions of the thymus and exiting into the periphery as a mature circulating T cell (surface CD3+, CD2+, CD5+, CD7+, either CD4+ or CD8+, CD1a- and TdT-). The differentiation, or transition, between these stages of maturation is a process in which antigen expression changes over time albeit with varying time frames. Patterns of staining reflecting this varying changes in antigen expression reflective of this maturation process are helpful in differentiating T-LBL/T-ALL from the normal thymic T cells seen in thymoma.

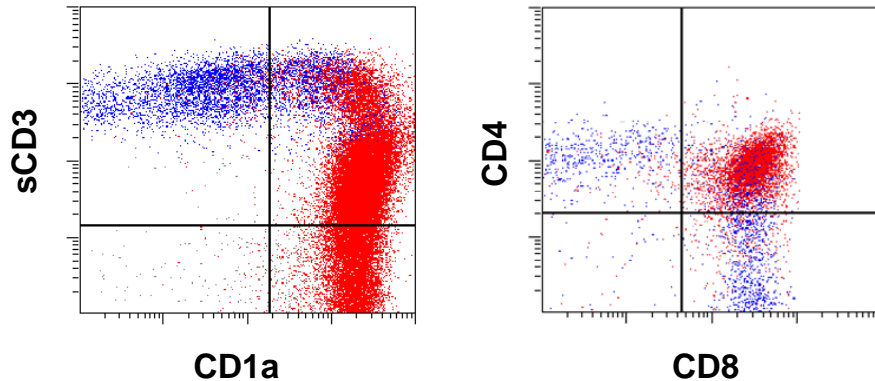
## T CELL LYMPHOMA ANALYSIS: Lymphoblastic Lymphoma/Leukemia

- 45 year old male
- Chest x-ray revealed mediastinal mass
- Enlarged thymus/mediastinal mass (135 grams; 9.3 X 7.5 X 6.3 cm) removed
- Received portion of biopsy for flow analysis

Charles Goolsby, PhD

In this example, a middle aged male presents with a mediastinal mass described above. The initial look at morphology was highly suspicious for T-LBL. Sample was sent for flow cytometry as well as IHC ordered including anti-cytokeratin.

## Lymphoblastic Lymphoma/Leukemia: Pattern of expression



Charles Goolsby, PhD

In the immunophenotype results above for surface CD3 (sCD3), CD1a, CD4 and CD8 on this tissue from a typical case of thymoma with reactive expansion of the thymic T cells, we see very different patterns of staining than that seen in the example for a typical T-LBL/T-ALL shown earlier. In the distribution of sCD3 versus CD1a we see a very heterogeneous pattern of staining going from sCD3-, CD1a+ to sCD3+, CD1a- and everything in between reflective of the underlying T cell differentiation ongoing in the thymus. Similarly, in the CD4 versus CD8 distribution, evidence of this differentiation process can also be seen with the majority of the cells being CD4/CD8 co-expressing with tails of staining into the CD4+CD8- and CD8+CD4- regions reflective of cells intermediary in this differentiation process. Contrast this with the discrete CD4/CD8 seen in T-LBL/T-ALL in the earlier example of T-ALL/T-LBL. Even when peripheral blood may contaminate the tissue sample in T-ALL/T-LBL, the singly positive cells will be discretely separated from the tumor cells and not show the intermediary cells seen in this example of non-malignant thymic T cells in thymoma, similarly in the sCD3 and CD1a distribution the continuum of intermediary cells will not be there.

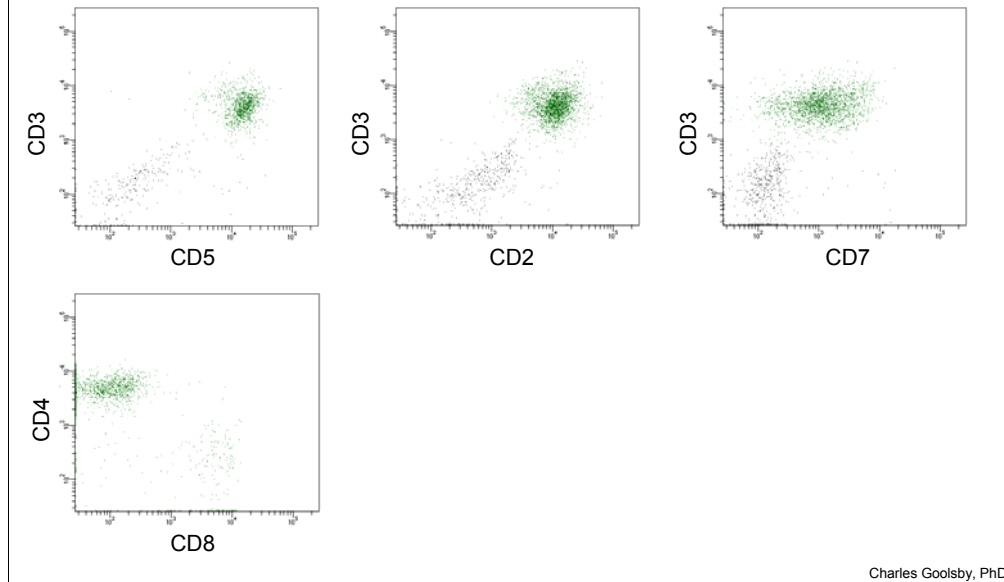
## T CELL LYMPHOMA ANALYSIS: Angioimmunoblastic Lymphoma

- AITL generally middle age to elderly
- Systemic disease
  - Lymphadenopathy
  - Hepatosplenomegaly
  - Skin rashes
  - Bone marrow involvement common
  - Most cases EBV+
- Increased helper to suppressor ratio
  - Pan T cell antigens can be altered but frequently not
  - CD10 can be positive

Charles Goolsby, PhD

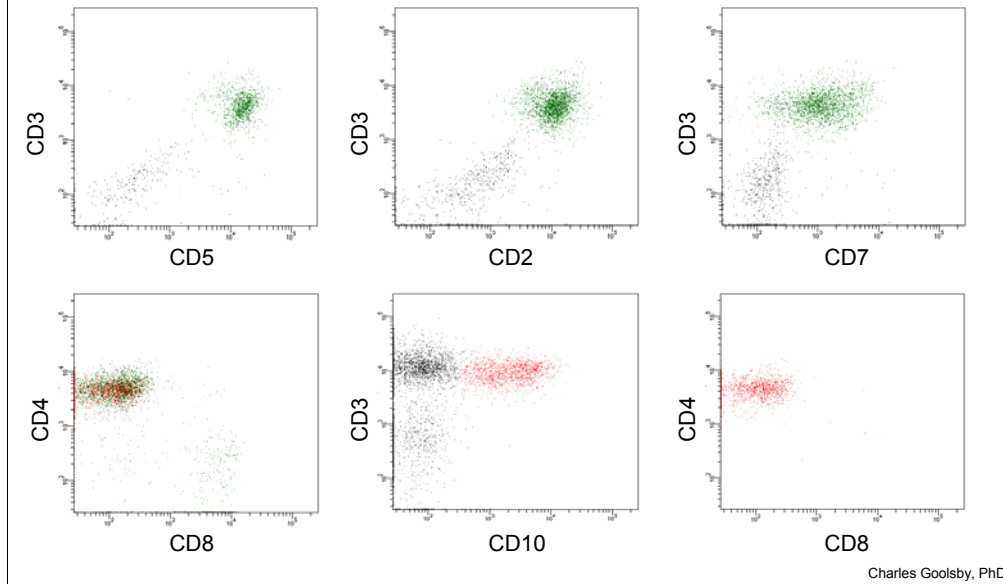
In addition, to alteration (loss, altered expression intensity) of pan T cell antigens described above, T cell lymphomas can also show immunophenotypes that are frankly aberrant in expression of other antigens or have immunophenotypes that overlap with rarer normal T cell subsets. Angioimmunoblastic lymphoma, the characteristics of which are described in this slide, represents one of these lymphomas.

## Angioimmunoblastic Lymphoma: Aberrant antigen expression



This is a typical result for a commonly analyzed set of T cell associated antigens in a case of AITL. The top row of histograms is gated on on the lymphocyte population, thus including, the B cells in this sample as a representative non-reactive, negative control, population for the T cell antigen staining. The CD4 versus CD8 histogram is gated on the surface CD3+ cells from the lymphocyte population. This pattern of staining (CD2+, surface CD3+, CD5+, CD7+) looks remarkably normal with the exception of slightly increased CD4+ to CD8+ cell ratio.

## Angioimmunoblastic Lymphoma: Aberrant antigen expression



However, when we look at CD10 staining in the T cells we see a clear CD10+ subset of the T cells. This subset is entirely CD4+ and CD8-. This pattern of staining is very typical of AITL in which the pattern of staining for the pan T cell antigens is not abnormal, or aberrant, with often only modest increases in the CD4 to CD8 ratio seen, clearly a pattern that can be seen in many reactive settings. It is only when specifically examining and selecting the CD10+ subset that one identifies the abnormal population. It should be noted that in some cases of AITL, alterations in other T cell antigens can be seen.

In many laboratories, CD10 is not analyzed in combination with T cell antigens but more typically is assessed in combinations focusing on the B cells. In that case, one should be cognizant of any CD10 staining not associated with the B cells when examining the lymphocytes in a sample. That can be a tip off to the presence of an abnormal T cell population and the need to examine CD10 specifically in the T cells. A note of caution is that the immunophenotype of AITL overlaps with a rarer, germinal center, T cell subset which is CD10+ and CD4+. These cells are generally seen at very low levels in most lymph node samples but one would want to be cautious in over interpreting the presence of a small population of CD10+ T cells in a lymph node. Aberrancies in staining of other T cell antigens can also be seen and can be helpful in that setting.

## T CELL LYMPHOMA ANALYSIS: Gamma/Delta T cell lymphomas

- Rare T cell lymphomas (<5% of T cell lymphoma)
- Hepatosplenic T-cell lymphoma
  - Although rare,
    - cutaneous/muccosal associated form
    - LGL
- Poor prognosis (except rare LGL form)
- Hepatosplenomegaly (lymph node involvement rare)
- Bone marrow/peripheral blood involvement common
  - Marked thrombocytopenia, anemia
  - Leukocytosis
- Reactive  $\gamma/\delta$  processes do occur
  - Immune suppressed setting
  - ...

Charles Goolsby, PhD

The T Cell Receptor, or TCR, expressed on mature (surface CD3+) T cells is composed of either a pairing of alpha ( $\alpha$ ) and beta ( $\beta$ ) chains or gamma ( $\gamma$ ) and delta ( $\delta$ ) chains. The vast majority of circulating T cells are  $\alpha/\beta$  T cells with only small percentages, typically less than 3%,  $\gamma/\delta$  T cells seen, although the percentage of these cells is higher in skin or other tissue sites. It should also be noted that increases in the numbers of these cells in the peripheral blood or bone marrow can also be seen in a number of reactive processes and in some immune deficient settings. However, as outlined above, malignant proliferations of these cells are also seen.



## T CELL LYMPHOMA ANALYSIS: Gamma/Delta T cell lymphomas

- Immunophenotype
  - $\gamma/\delta+$ ,  $\alpha/\beta-$
  - sCD3+, CD2+, CD7+
    - Most frequently CD5-
  - CD4-, CD8-
    - Rare positive, usually dim
  - TIA1+
    - Perforin negative
    - CD56+/-, CD16 +/- (usually CD57-)

Charles Goolsby, PhD

The archetypical gamma/delta T cell lymphoma being splenic T cell lymphoma. The most frequent immunophenotype of this disease is listed above. Note that these cells often have the phenotype of a normal gamma/delta T cell, although deletion of CD5 is frequently seen. The cytotoxic associated antigens are generally positive with the exception that the cells are generally CD57- and perforin negative.

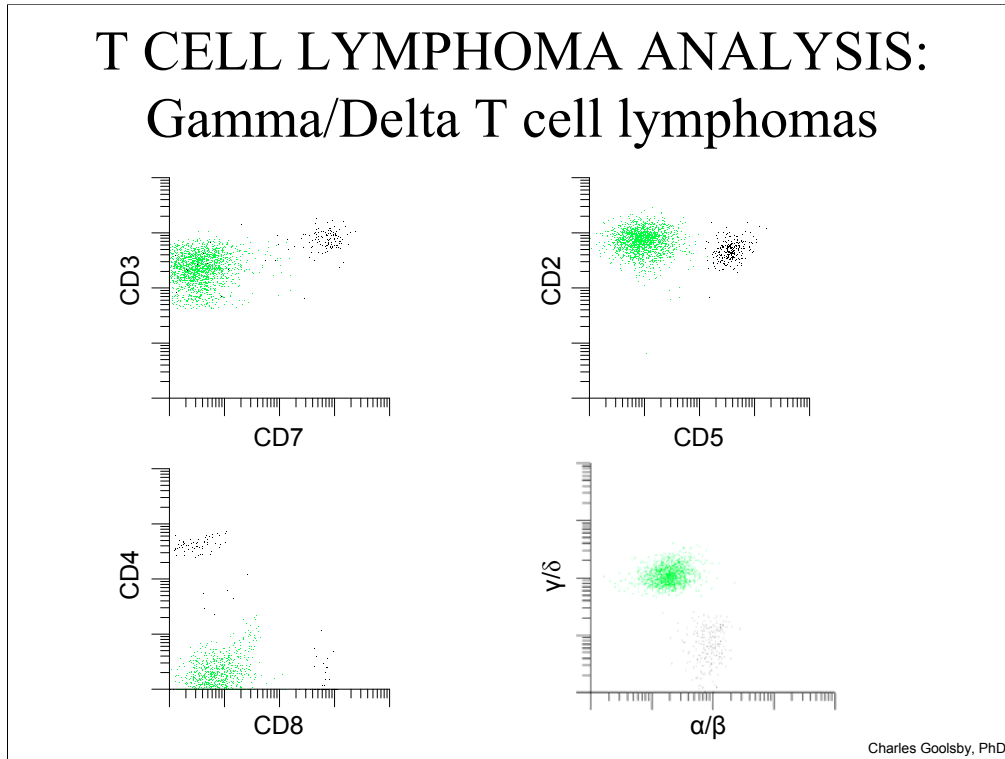
## T CELL LYMPHOMA ANALYSIS: Gamma/Delta T cell lymphomas

- 19 year old male
- Thrombocytopenia
- WBC: 85.6
  - Circulating “blast” cells
- Enlarged spleen
- Bone marrow aspirate received

Charles Goolsby, PhD

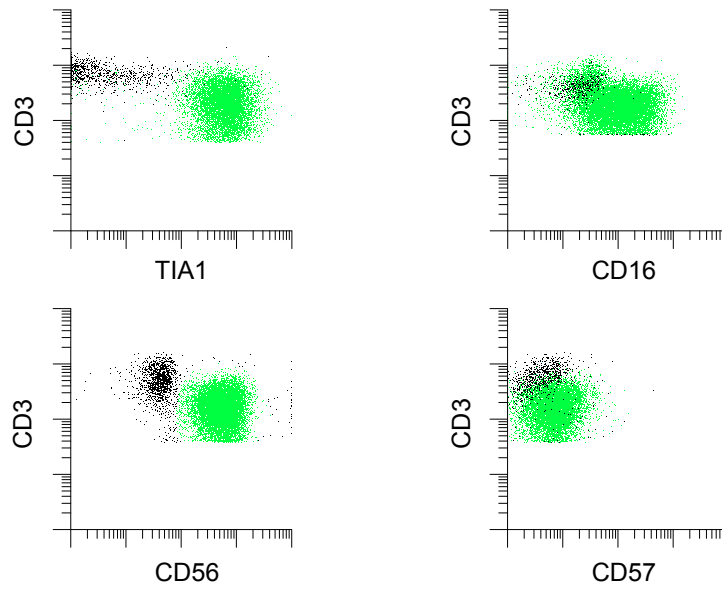
The presenting characteristics for this young male with splenic T cell lymphoma are shown above

## T CELL LYMPHOMA ANALYSIS: Gamma/Delta T cell lymphomas



The immunophenotype for this patient are shown above and in the next slide. The abnormal cells are shown in green above and are surface CD3+ and CD2+ but CD5- and CD7- as well as CD4-, CD8-, ( $\gamma/\delta$ )+, and ( $\alpha/\beta$ )-

## T CELL LYMPHOMA ANALYSIS: Gamma/Delta T cell lymphomas



Charles Goolsby, PhD

Further, these cells express the typical pattern of TIA1+, CD16+, CD56+ and CD57-

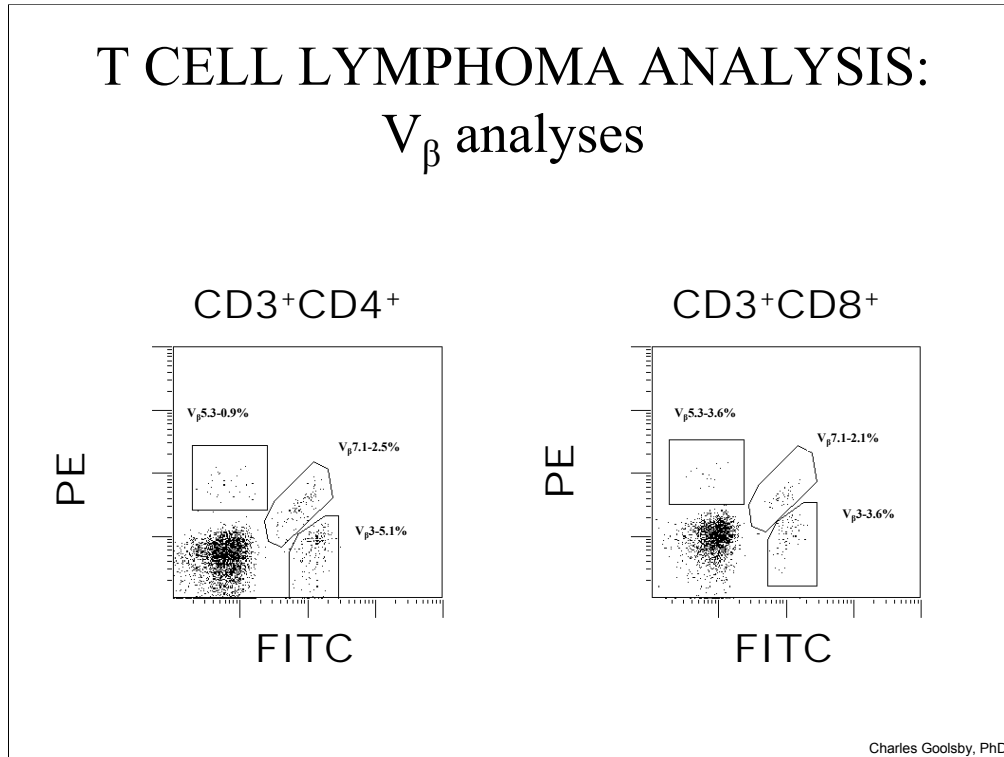
## T CELL LYMPHOMA ANALYSIS: $V_{\beta}$ analyses

- T cell receptor has similar structure to immunoglobulin genes
- Over 90 variable region protein families
- Monoclonal antibodies specific for each family
  - Expressed at a few percent or less each in any given T cell sub-population
  - In malignant, clonal cells only one will be expressed

Charles Goolsby, PhD

Flow cytometry can provide a sensitive and specific measurement of clonality in T cells. The T cell receptor genes have a similar structure to other immunoglobulin genes with constant, variable, diversity, and joining region genes. Similar to B cells, the T cell receptor gene family also undergoes allelic restriction of these genes. However, unlike B cells where one needs only to examine two gene products (proteins), kappa and lambda, to determine if there has been a clonal expansion, with T cells there are over 90 variable region gene, or protein, families potentially needing to be assessed. Each of these family members is expressed at a few percent or less in any normal T cell subset. Seeing exclusive use of only one T cell receptor gene set (family) in a subset of T cells is indicative of clonality. However, as noted, to cover the entire T cell repertoire requires assessing staining of 90 or more antibodies as compared to only kappa and lambda in B cells making it a much more cumbersome and expensive endeavor. For these reasons, assessment of clonality in T cells is not routinely done by most clinical flow cytometry laboratories. However, each of the variable region gene families are not equally utilized and assessing a subset of 24 members can cover 70% of the expressed repertoire.

## T CELL LYMPHOMA ANALYSIS: V<sub>β</sub> analyses

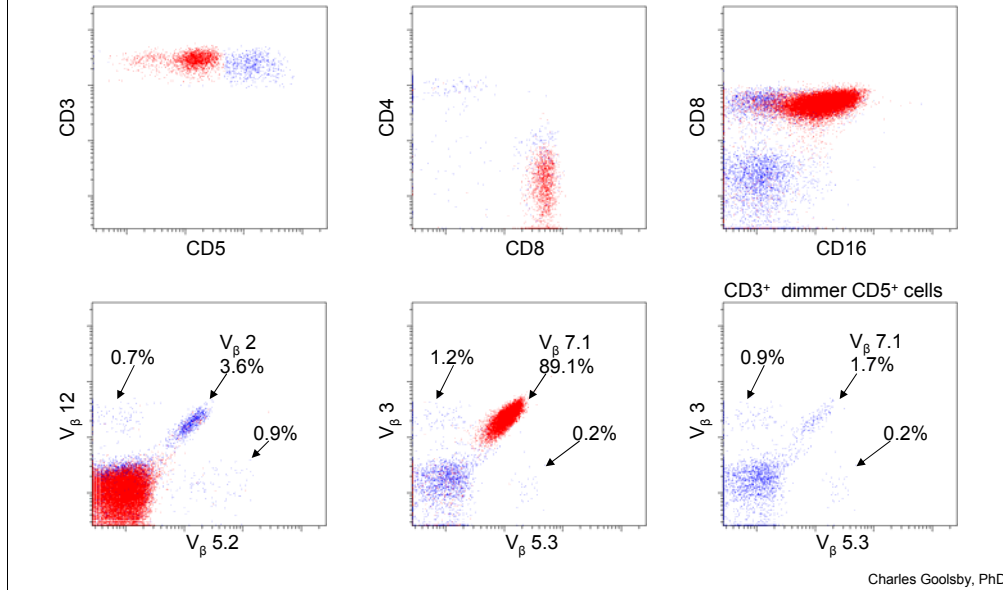


In this slide is shown the typical pattern seen for expression of the TCR variable region gene family proteins (in this example V<sub>β</sub>5.3, V<sub>β</sub>7.1, and V<sub>β</sub>3) in a normal donor for the CD3+CD4+ and CD3+CD8+ T cell subsets. In this reagent set, V<sub>β</sub>5.3, V<sub>β</sub>3, and V<sub>β</sub>7.1 are labelled with PE, FITC and with both PE and FITC, respectively. In this way, one can assess three V<sub>β</sub>s in one tube using only two fluorophores still allowing assessment of other antigens to examine expression in specific subsets of T cells. Using this approach allows one to examine the 24 variable region protein families that cover 70% of the expressed repertoire in only 8 tubes. Obviously, with the now routine use of higher numbers of parameters (more colors), this could be made even more efficient if one were willing to make the reagents to do this. This will obviously not reduce the cost of these analyses but certainly would make them less cumbersome.

The pattern of expression seen in this slide for V<sub>β</sub>5.3, V<sub>β</sub>3, and V<sub>β</sub>7.1 is typically of what is seen in normals for all the V<sub>β</sub> proteins. One sees a small percentage of cells positive for each V<sub>β</sub>. Contrast this with what is seen when a clonal T cell subset is present which is shown in the next slide.

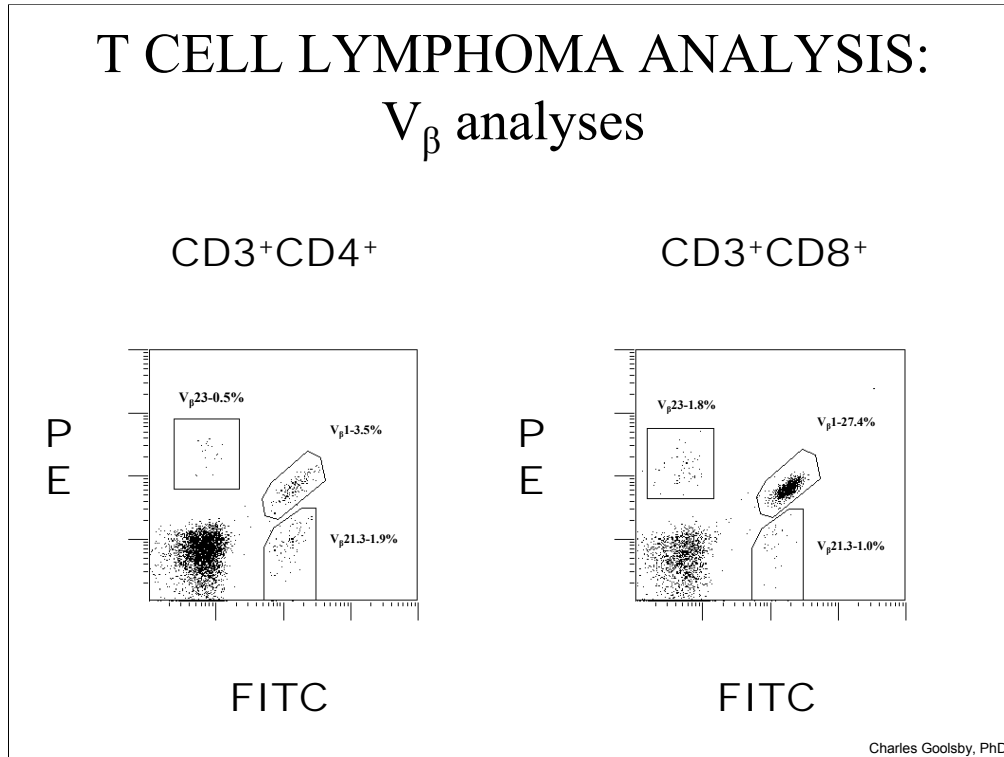
# T CELL LYMPHOMA ANALYSIS:

## $V_{\beta}$ analyses



In this example, we see a T cell population with bright CD3+ and discretely dimmer CD5+ staining shown in red which is CD8+ and CD16+. This population was also CD56+, CD57+, TIA1+, granzymeB+, and perforin+ representing the abnormal cells in a large granular lymphocyte (LGL) leukemia case. The results for staining of nine of the V proteins is shown in the lower row of histograms with the abnormal cells shown in red and the normal T cells shown in blue. The normal T cells show a typical, normal, pattern of V $\beta$  protein expression with a few percent or less positive cells for each V $\beta$  tested. However, within the abnormal T cells shown in red we see that they are exclusively V $\beta$ 7.1+ and negative for the other V $\beta$ 's shown indicative of the clonal nature of this abnormal T cell population.

## T CELL LYMPHOMA ANALYSIS: V<sub>β</sub> analyses



Charles Goolsby, PhD

In this example from another patient are shown staining for three V<sub>β</sub> proteins, 23, 1 and 21.3, in the CD3+CD4+ and CD3+CD8+ subsets. Within the CD3+CD8+ subset, although not exclusive expression of one V<sub>β</sub>, we do see significant expansion of cells expressing V<sub>β</sub>1 over normal levels, in this case some 10 fold over the upper limit of the normal range for V<sub>β</sub>1. This is an example from a CLL patient in which the majority of the lymphocytes were a CD5+CD19+ monoclonal B cell population. In a large series of CLL patients, we found that all had evidence, both by V<sub>β</sub> analyses and by molecular studies, of either clonal or oligoclonal expansions within the T cell population. In this setting, the most frequent finding is similar to above where rather than finding exclusive use of one V<sub>β</sub>, the most frequent finding is over utilization, but not exclusive use, of one V<sub>β</sub>. Typically, in T cell malignancies, one finds the immunophenotypically defined abnormal subset to be all one V<sub>β</sub>. Thus, the warning would be to not over interpret over utilization, or expansions, of V<sub>β</sub> expressing populations when it does not reflect all, or the vast majority, of the cells in the defined subset. Reactive oligoclonal, and even clonal, expansions of T cells are frequently seen in a variety of disorders including B cell malignancies, in the non-malignant T cells in T cell lymphomas, solid tumors, and autoimmune disorders. It would appear that reactive oligoclonal, and even clonal in some cases, expansions of T cells is a common reactive response. Nonetheless, when seen, it should be noted that it can be a clue to look more carefully for a better, or more finely, defined subset of the T cells in which to examine V<sub>β</sub> expression.



# T CELL LYMPHOMA ANALYSIS: $V_{\beta}$ analyses

- T cell receptor has similar structure to immunoglobulin genes
- Over 90 variable region protein families
- Monoclonal antibodies specific for each family
  - Expressed at a few percent or less each in any given T cell sub-population
  - In malignant, clonal cells only one will be expressed
- Oligoclonal (clonal?) expansions can be seen in many non-T cell malignant settings
  - Virtually all B cell lymphomas (Tumor specific expansions)
  - Autoimmune settings
  - Even in T cell malignancies
  - .....
  - Expensive and cumbersome

Charles Goolsby, PhD

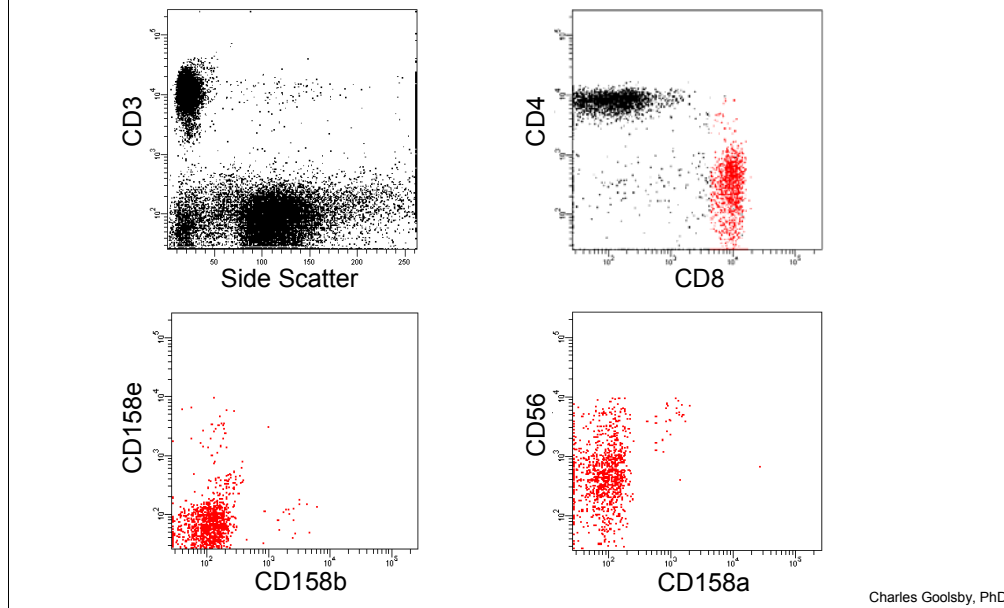
## T CELL LYMPHOMA ANALYSIS: NK, cytotoxic T, LGL surrogates of clonality

- $V_{\beta}$  analyses
- Killing Inhibitory Receptors (KIRs)
  - Family of proteins that can positively or negatively regulate cytotoxic cell activity
    - CD158a, CD158b, CD158e, .....
  - Expressed on cytotoxic T and NK cells
    - Stable expression over multiple cell generations
  - Malignant one can see high expression of only one family member in abnormal cells
    - Surrogate of “clonality”
      - Not allelic restricted like TCR
    - Not always expressed in T cells
      - Should always be expressed in NK cells

Charles Goolsby, PhD

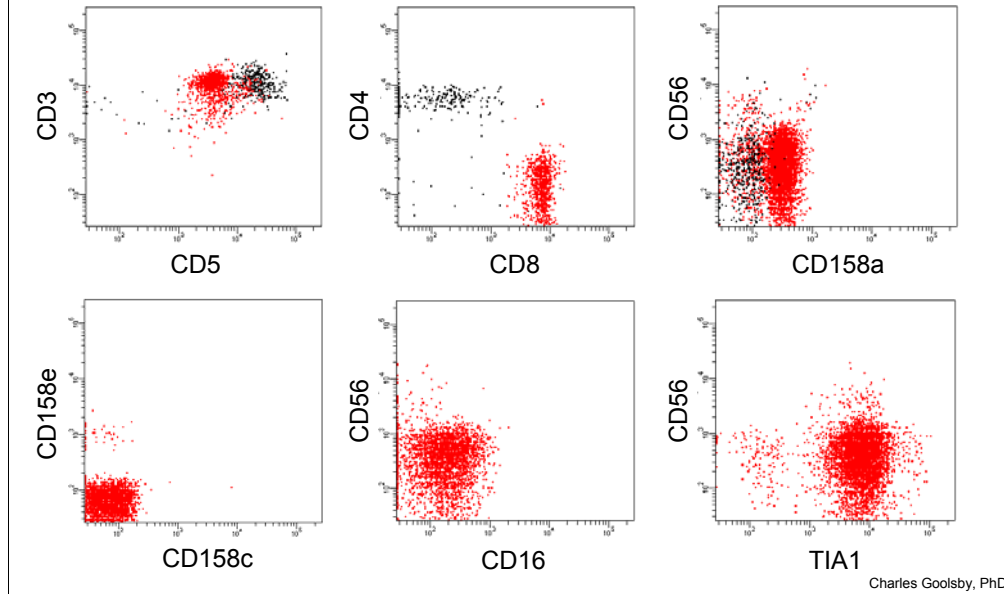
One last topic on clonality. KIRS are a family of proteins that regulate, either promoting or inhibiting, cytotoxic cell activity depending on the milieu in which they are expressed. These proteins are expressed in all mature NK cells and at least in mature NK cells are not co-expressed. In cytotoxic T cells, one normally sees only a small percentage of cells positive for any one of the KIRS with many cells being negative at least for the common three KIRS proteins that are assessed by flow cytometry, CD158a, CD158b, and CD158e. Although not allelically restricted as TCR genes are, the KIRS expression pattern is inherited by daughter cells. Thus, seeing the vast majority of cells in an immunophenotypically selected subset of cytotoxic NK or T cells implies clonality. Assessment of KIRS expression in NK cells works well as it is almost always expressed and when it is not, it is abnormal. When expressed in cytotoxic T cells it can also be helpful, however, it is frequently not expressed.

## T CELL LYMPHOMA ANALYSIS: NK, cytotoxic T, LGL surrogate of clonality



Shown above is an example of KIRS expression in normal CD8 T cells with only a small percentage of cells positive for each of the KIRS tested.

## T CELL LYMPHOMA ANALYSIS: NK, cytotoxic T, LGL surrogate of clonality



Contrast this with an example of another T LGL leukemia case in which abnormal cells showed all the abnormal CD8+ cells were CD158a+ and CD158c and CD158e negative.

# T CELL LYMPHOMA ANALYSIS

- Diverse group of malignancies
- Aberrant immunophenotypes
  - Pan T cell antigen loss/altered expression
    - Must rule out epitope deletion or masking
  - Predominance of one subset (although can be CD4- and CD8-)
    - Significant skews can be seen in non-malignant settings
      - CD4:CD8 >12 to 15 unusual in reactive
      - CD8 expansions can be quite marked
  - Aberrant combinations of antigens
  - Characteristic expression of antigens
  - Pattern of expression
  - Clonality
    - $V_{\beta}/V_{\alpha}$  analyses: sensitive but seldom done
    - Surrogates
    - Malignant? Not necessarily
- Significant overlap with patterns that can be seen in reactive
- Careful correlation with clinical and pathology
  - Classification depends on clinical

Charles Goolsby, PhD

# T CELL LYMPHOMA ANALYSIS

## Northwestern Memorial Clinical Flow Cytometry Laboratory

Laura Marzalek  
Janet McLaughlin  
Keisha Hughes

Adella Khong  
Carolina Ostiguin  
Maybelle Tiongson

Charles Goolsby, PhD

In closing, I just want to thank the Northwestern Clinical Flow Cytometry Laboratory whose efforts and talent underlie all the work shown.

# T CELL LYMPHOMA ANALYSIS

- Borowitz MJ, Chan JKC. "T lymphoblastic leukaemia/lymphoma" in "WHO classification of tumors of haematopoietic and lymphoid tissues" Eds. Swerdlow SH, Campo E, Harris NL, Jaffe ES, Pileri SA, Stein H, Thiele J, Vardiman JW. 176-178, 2008.
- Multiple sections and authors, Chapter 11 "Mature T- and NK-cell neoplasms" in "WHO classification of tumors of haematopoietic and lymphoid tissues" Eds. Swerdlow SH, Campo E, Harris NL, Jaffe ES, Pileri SA, Stein H, Thiele J, Vardiman JW. 269-319, 2008.
- Willemze R, Jaffe ES et al. "WHO-EORTC Classification for Cutaneous Lymphomas" Blood 105 (10): 3768-3785, 2005.
- Morice WG, Kurtin PJ et al. "Demonstration of aberrant T-cell and natural Killer-Cell Antigen Expression in all cases of Granular Lymphocytic Leukaemia" British J Haematology 120:1026-1036, 2003.

Charles Goolsby, PhD

Listed are several general references which may be useful in addition to those listed above on more specific topics.